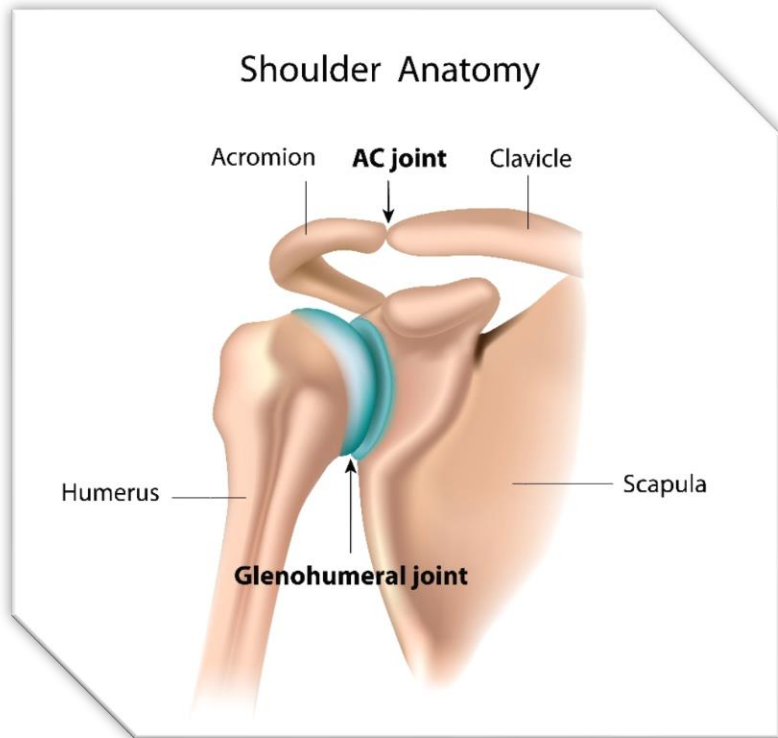


The Shoulder or Glenohumeral Joint



Shoulder joint Facts:

The glenohumeral joint is an articulation between the head of the humerus and the glenoid cavity of the scapula.

Within the glenohumeral joint is a fibrocartilage that deepens the glenoid cavity. This fibrocartilage is known as the labrum and it helps to stabilize the head of the humerus within the glenohumeral joint.

The Shoulder Joint

Glenohumeral joint – diarthrodial – ball and socket

